

Anti-OX40 monoclonal antibody IMG-007 exhibited clinical activity of hair regrowth, suppressed scalp inflammatory biomarkers in patients with severe alopecia areata in a Ph1b/2a study

Emma Guttman¹, Maryanne Senna², Dusan Sajic³, Catherine Maari⁴, Megan Lau¹, Joseph Lagen¹, Ester Del Duca¹, Juliana Pulsinelli¹, Joel Correa da Rosa¹, Chongtian Guo⁵, Yancong Shen⁵, Yufang Lu⁵

1.Department of Dermatology, Icahn School of Medicine at Mount Sinai, New York, USA, 2.Harvard Medical School, Boston, MA, USA, 3.Guelph Dermatology Research, Guelph ON, Canada, 4.Innovaderm Research, Montreal, QC, Canada, 5.ImageneBio, Inc, USA

Introduction

- Alopecia Areata (AA) is a prevalent chronic autoimmune disease characterized by nonscarring hair loss involving the scalp, face, and/or body. There are few viable therapeutic options with no approved targeted biologic therapy for AA patients.
- The pathogenesis of AA involves the collapse of follicular immune privilege leading to perifollicular infiltration of immune cells including CD4+ and CD8+ T cells.
- Increased circulating OX40+ cells and upregulation of OX40 and OX40L expression in the scalp of AA patients has been shown previously.
- IMG-007 is a novel anti-OX40 monoclonal antibody (mAb) that blocks OX40-OX40L signaling without depleting T cells and has an extended half-life.
- Here we report safety, clinical activity, and biomarker results from a phase 1b/2a, study of IMG-007 in severe AA patients.

Conclusions

- Treatment with three doses of IMG-007 300 mg and 600 mg over four weeks resulted in a dose-related clinical activity signal of hair regrowth.
- Patients in the 600 mg group showed a progressive SALT score reduction without plateauing by week 36, which is ~8 months after the last dose.
- Four-week treatment with IMG-007 600 mg resulted in a broad and durable suppression of activated T cell expression and partial restoration of hair keratins in scalp biopsies.
- IMG-007 was overall well-tolerated in patients with severe AA.
- These results suggest that blocking OX40-OX40L signaling with IMG-007 could be a potential therapeutic strategy for treating AA patients.

Methods

Study Design

- This was an open-label study enrolling participants with severe AA, as measured by the severity of alopecia tool (SALT) score of ≥ 50 at screening and baseline visits. Patients received up to three intravenous doses of IMG-007 at 300 mg/dose or 600 mg/dose over 4 weeks (at weeks 0, 2 and 4) and followed up to Week 36.
- Key study endpoints were safety, assessed by the incidence of treatment-emergent adverse events (TEAEs), and clinical activity, measured by the percentage change from baseline in SALT score by visit. Pharmacodynamic effect was explored by transcriptomic and histological evaluations of scalp biopsies.

Scalp Biopsy Biomarker Analysis

- Lesional scalp biopsies were collected at baseline and week 16. Non-lesional biopsies from an un-involved area adjacent to the lesions were also collected at baseline.
- Biopsies were bisected for transcriptome sequencing and immunohistochemical (IHC) staining, respectively. Change in transcriptional expression was calculated as previously reported¹. For IHC data, staining positive cell counts or staining intensity was analyzed.

Results

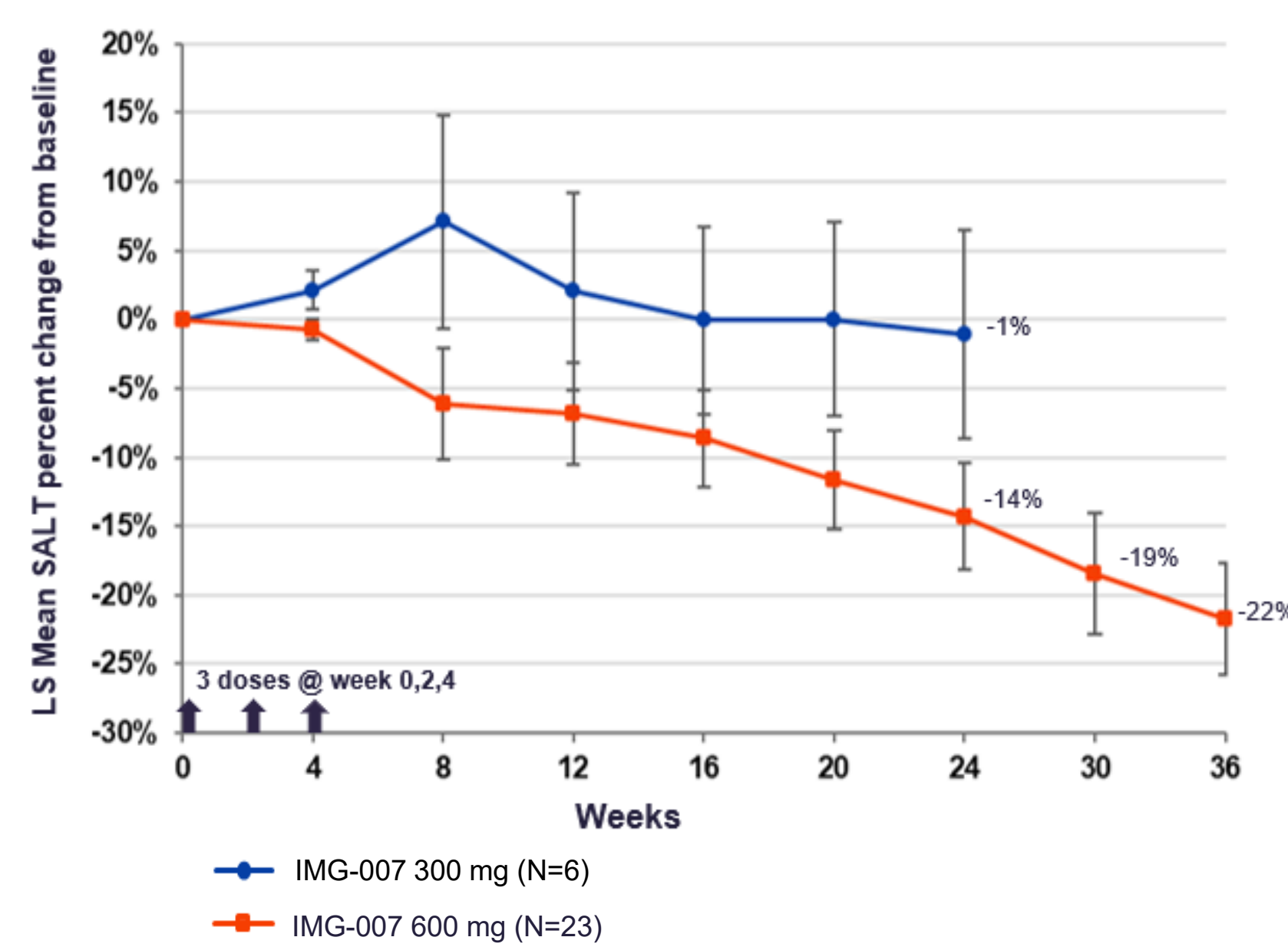
Baseline Demographics and Disease Characteristics

- A total of 29 patients were enrolled from 11 centers in the U.S. and Canada (N=6 in 300 mg group and N=23 in 600 mg group).
- Approximately 76% of enrolled patients were female, 66% of them were white, and 24% were black.
- Mean duration of current AA episode was 3.0 years; Mean SALT score was 80.4; 69% of all patients had SALT scores 50 to <95 and 31% had scores of ≥ 95
- In the 600 mg group, 16 patients also participated in an optional extended follow-up period up to week 36

Clinical Activity Results

- A dose-related trend in SALT reduction was observed. SALT scores remained generally unchanged over 24 weeks in the 300 mg group. Participants in the 600 mg group showed progressive SALT reduction without plateauing by week 36, approximately 32 weeks after the last dose (Figure 1).
- In the 600 mg group, participants with baseline SALT 50 to <95 (N=17) showed greater SALT improvement than those with baseline SALT ≥ 95 (N=6), Figure 2.

Figure 1. Percentage Change From Baseline in SALT Score in Full Analysis Set



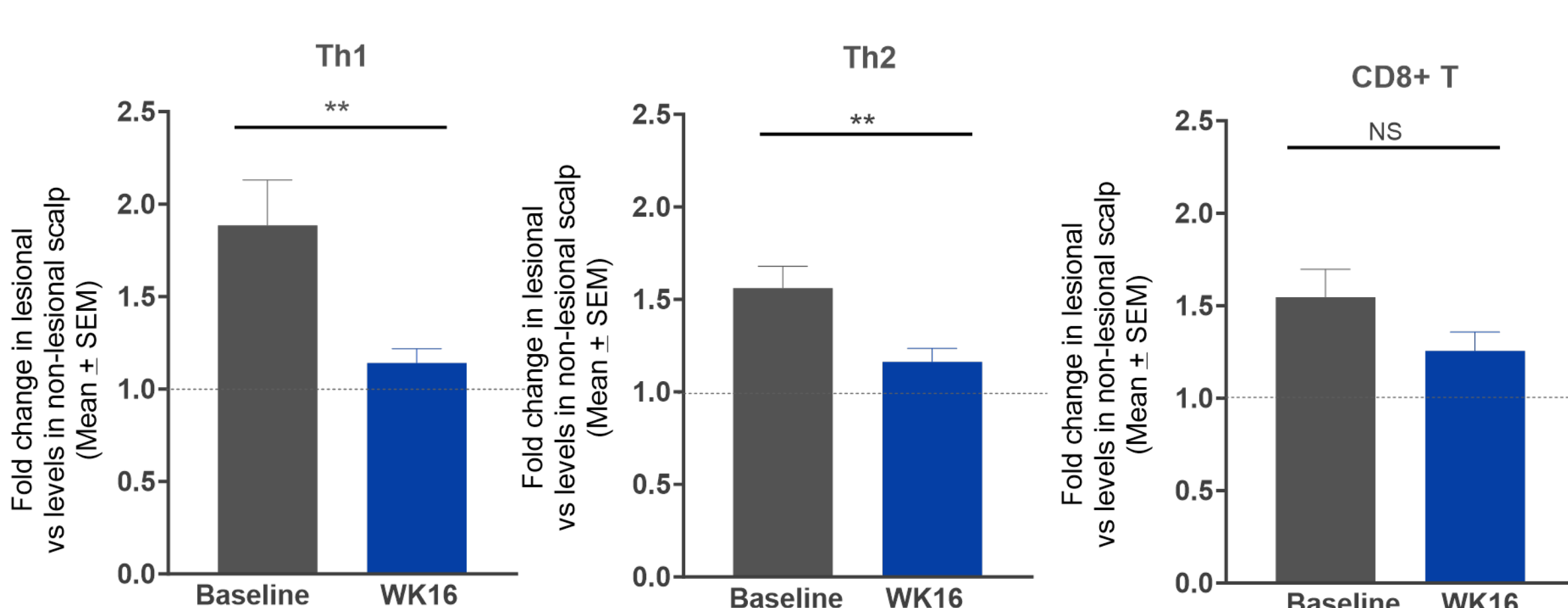
Full analysis set included all enrolled patients who received at least one dose of study treatment.

For the percentage change from baseline in SALT, a mixed model repeated measure (MMRM) analysis was performed. Data after prohibited medications was set to missing.

Scalp Biopsy Biomarker Results

- Twenty-three and 17 patients provided baseline and week 16 lesional scalp biopsies, respectively, and 14 provided baseline non-lesional biopsies.
- At baseline, patients exhibited molecular signatures of activation of various subtypes of effector T cells (Figure 3). These results are consistent with data previously reported.
- Baseline upregulated lesional expression of genes of Th1, Th2 and CD8+T cells were broadly normalized to levels of non-lesions at week 16 (Figure 3).
- Lesional expression of hair-associated keratin genes at baseline were downregulated. A trend of increased KRT35 IHC expression (an indicator of early stage of hair differentiation) in lesions was noted at week 16 (Figure 4).

Figure 3. Fold change in lesional vs. non-lesional scalp skin of Th1, Th2 and CD8+ T cell-related genes at baseline and Week 16

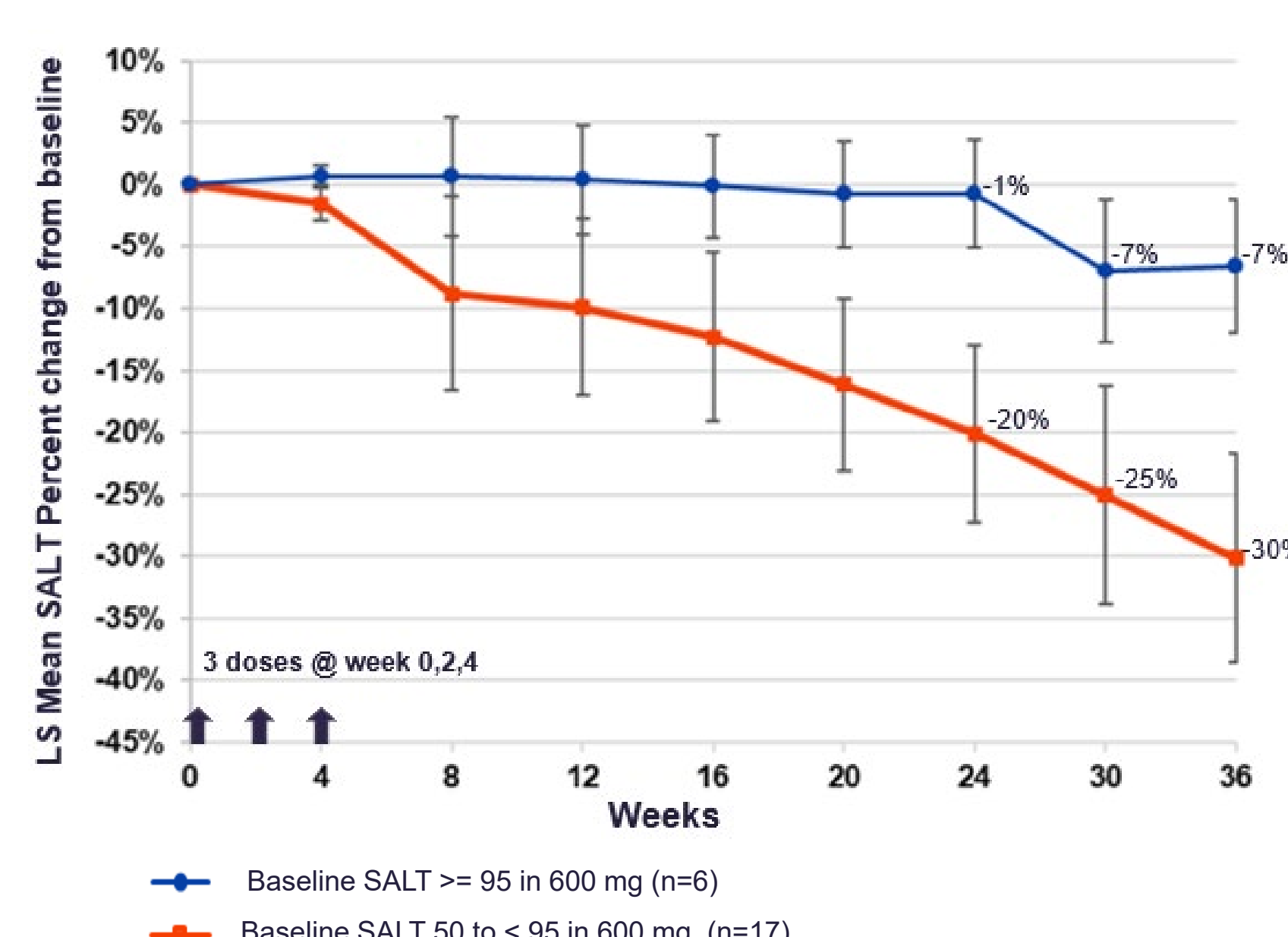


Dash line indicates levels in corresponding non-lesional scalp skin. For lesional scalp expression levels (600mg group), Ns at Baseline and week16 were 23 and 17, respectively. Non-lesional scalp gene expression levels were measured in the corresponding non-lesional tissues, n=14. ** * p<0.01; NS: not significant, based on unpaired T-test

Disclosures:

Emma Guttman and Maryanne Senna are advisers for ImageneBio, the sponsor of the study. Yufang is an employee of ImaneneBio; Chongtian Guo and Yancong Shen were employees of ImageneBio when the study was conducted.

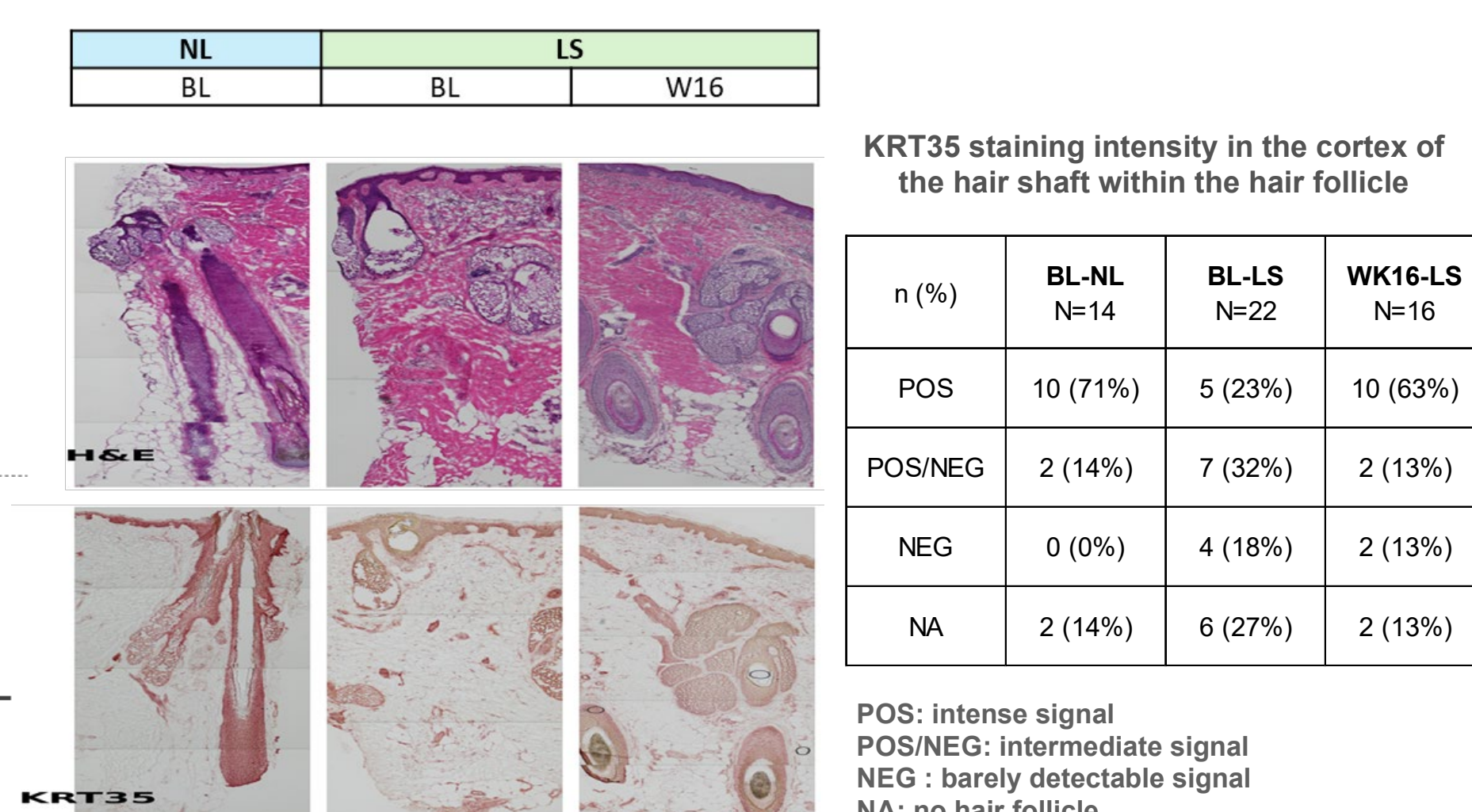
Figure 2. Percentage Change From Baseline in SALT Score by baseline SALT score 50 to <95 vs. baseline SALT ≥ 95



Photos showing improvement after 4-week treatment with IMG-007

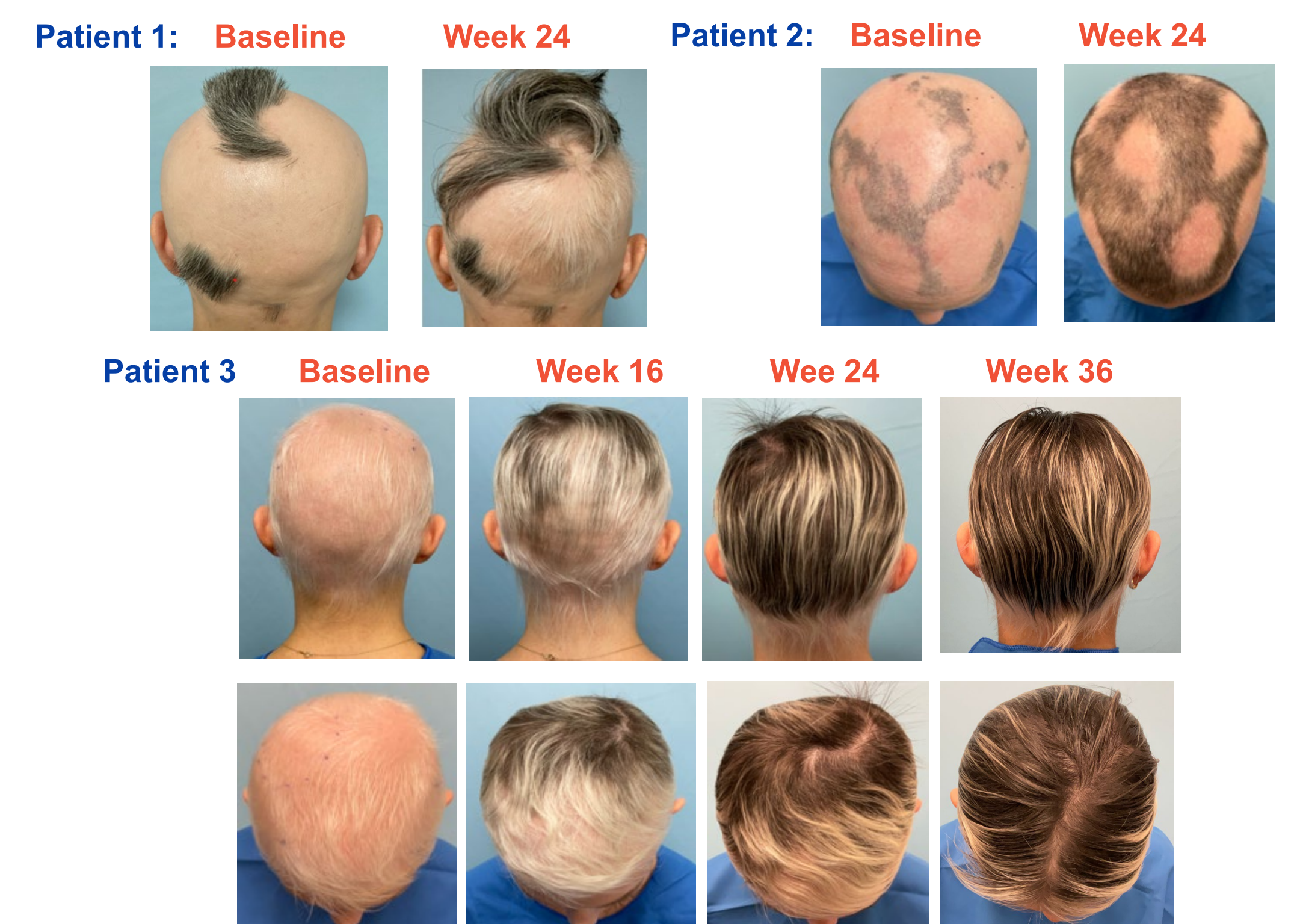

Figure 4. H&E and IHC Staining of KRT35 in scalp biopsies at baseline and Week 16



Shown is representative data depicting partial restoration of hair follicle structure and KRT35 expression (indicator of early stage of hair differentiation)

Safety Results

- IMG-007 was well-tolerated overall.
- All TEAEs were mild or moderate
- There were no serious AEs and no reported pyrexia or chills (Table 1).

Table 1. TEAEs in at least 2 participants in any treatment group during 24-Week Period

Preferred term	IMG-007 300 mg (N=6) n (%)	IMG-007 600 mg (N=23) n (%)	IMG-007 combined (N=29) n (%)
Headache	2 (33.3)	2 (8.7)	4 (13.8)
Nasopharyngitis	0 (0.0)	3 (13.0)	3 (10.3)
Hypertension	0 (0.0)	2 (8.7)	2 (6.9)
Streptococcal infection	0 (0.0)	2 (8.7)	2 (6.9)

TEAE incidence was generally similar between the 24-week and extended 36-week periods

Reference:

1. Guttman-Yassky E, Pavel AB, Diaz A, et al. J Allergy Clin Immunol, 2022;149(4):1318-1328.